

# Mammography plus Automated Breast Ultrasound (ABUS) results in improved earlier detection of breast cancer

## Introduction

While mammography remains the gold standard for detecting breast cancer, research has shown it is not equally effective in all women.<sup>1</sup> In the 40% of U.S. women with dense breast tissue, mammography can miss up to one third of breast cancers.<sup>2</sup> This may lead to a delay in diagnosis and a worse prognosis for women with dense breast tissue.

Mammography has been shown to miss 30% of cancer in dense breasts.<sup>3</sup> Using screening ultrasound for woman with dense breasts is helping address this challenge. However, the limitations of traditional hand-held ultrasound (HHUS), which include operator dependency, variability and long acquisition times, make it inefficient for broad-scale breast cancer screening. With the introduction of ABUS (automated breast ultrasound), clinicians are able to address these variables and shorten both exam and read times, while increasing sensitivity with a multi-modality approach.

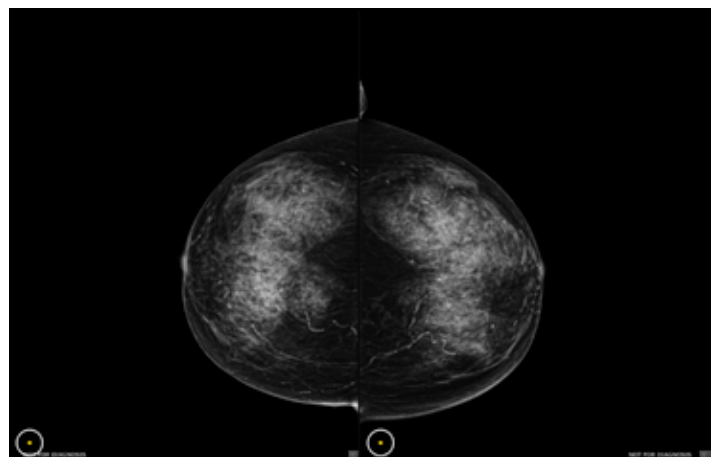
Clinical research studies demonstrate that when used as an adjunct to mammography, ABUS can detect small, invasive, node-negative cancers. The ability to find mammographically occult cancers at smaller sizes may translate into reduced mortality and lower morbidity for patients – while also creating the potential to reduce therapy costs.<sup>2</sup> The following cases demonstrate the clinical value of using ABUS as an adjunct screening for women with dense breast tissue.



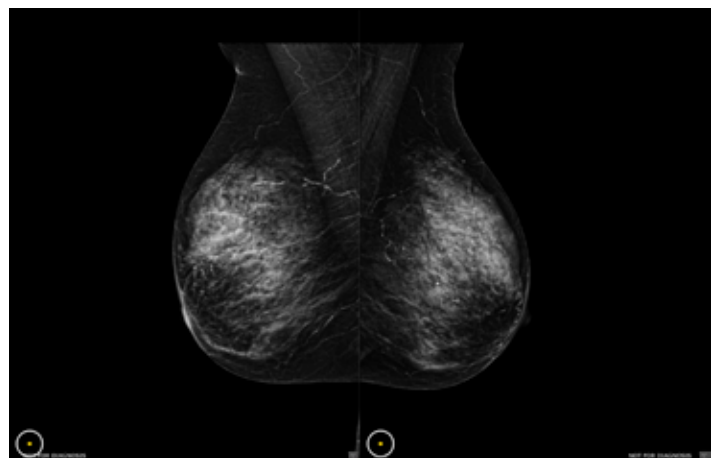
## Case Study 1

### Presentation

Healthy 82-year-old female presented for annual screening mammogram. Patient had no risk factors or family history, however presented with heterogeneously dense breasts, BI-RADS® density C, which warranted additional imaging beyond mammography.



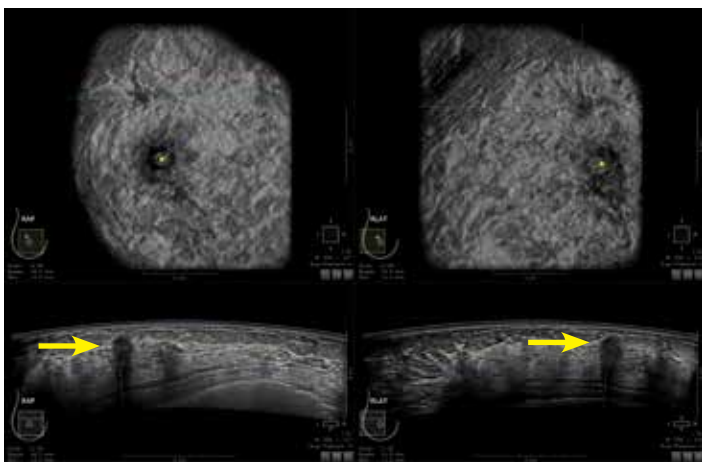
Normal Screening Mammogram (CC View)



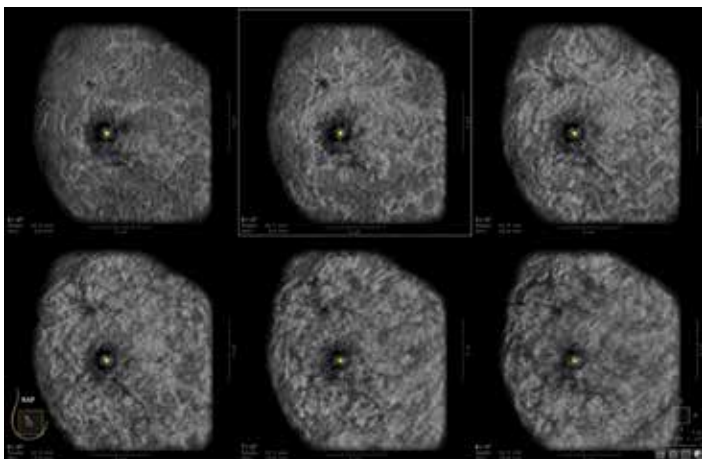
Normal Screening Mammogram (MLO View)

## Investigation and Diagnosis

Although the patient's mammograms had been stable for the last six years, the physician ordered an ABUS exam due to dense breast tissue. Upon ABUS detecting the abnormality that was later diagnosed as invasive ductal carcinoma with no positive nodes seen; she was referred for a hand-held targeted ultrasound, followed by an ultrasound-guided core biopsy. Once the pathology was confirmed, the patient was referred for an MRI to determine if additional disease was present. Although MRI did not find any other cancers or cysts beyond the initial ABUS findings, it further revealed additional information on the tumor. The dimensions of the cancer were found to be even larger than initially identified. The sagittal MIPS on MRI with thicker slabs facilitated visualization of the cancer.



Multi-planar and multi-volume correlation between the right anterior-posterior and right lateral views allows for efficient and concise confirmation of this biopsy-proven invasive ductal carcinoma



The multi-slice hanging layout clearly demonstrates this biopsy-proven invasive ductal carcinoma with size of lesion & location intervals

## Treatment

Patient received a homo-quadrantectomy and radiation, due to the location and extent of the cancer. She did not require a partial mastectomy or chemotherapy due to age and medical recommendations.

## Discussion

"Without risk factors or family history, and after years of negative mammograms, this cancer could easily have remained occult for much longer. All dense breasts are eligible for ABUS," Dr. Perez-Tamayo points out, adding that in this case, "age doesn't matter."

## Dr. Jose Perez-Tamayo



Dr. Perez-Tamayo is a practicing Diagnostic Radiologist at Utah Imaging Associates in Bountiful, Utah – where he is affiliated with three hospitals. He specializes in Mammography and Interventional Radiology. Dr. Perez-Tamayo's 20-plus year career began after studying at the University of Illinois College of Medicine,

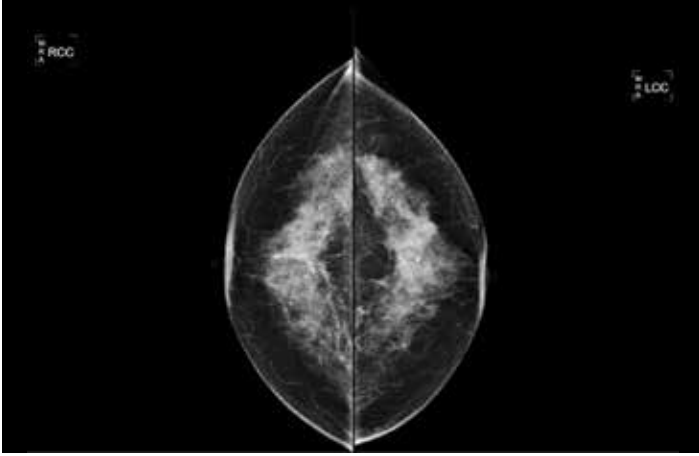
followed by his Internship at the Lincoln School of Medicine and Residency in Diagnostic Radiology at the University of Missouri Hospitals and Clinics. He is Board Certified in Diagnostic Radiology by the American Board of Radiology and has contributed to research publications on MRI and CT.

# Case Study 2

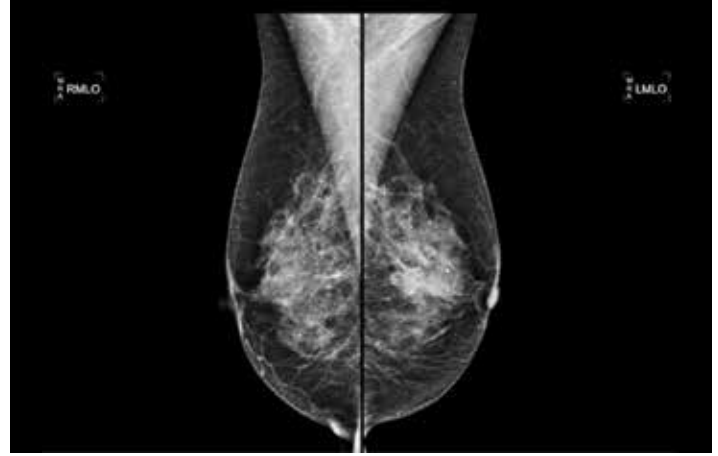
## Presentation

A healthy 56-year-old female underwent her annual mammogram. She had extremely dense breasts and has had previous biopsies. Prior mammograms were negative

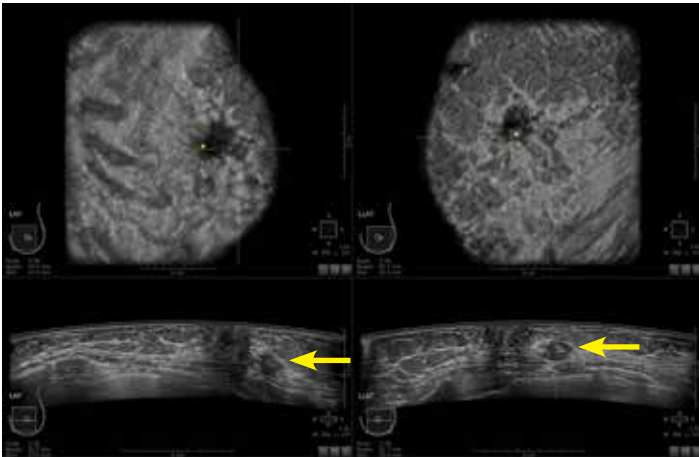
with the exception of some micro-calcifications and benign cysts with calcifications obscuring areas on the mammographic images.



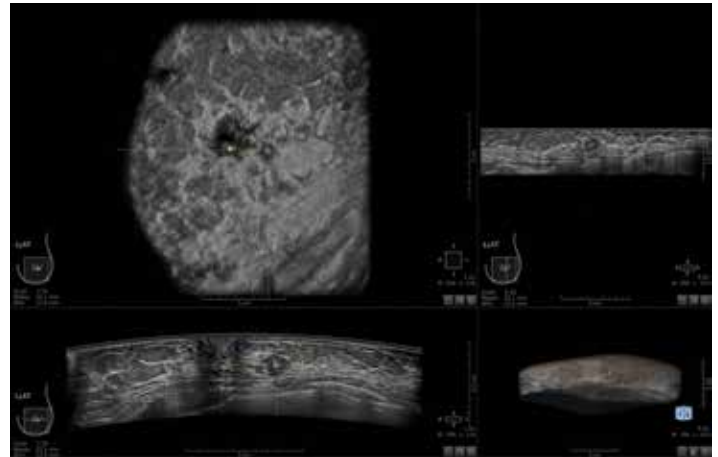
Normal Screening Mammogram (CC View)



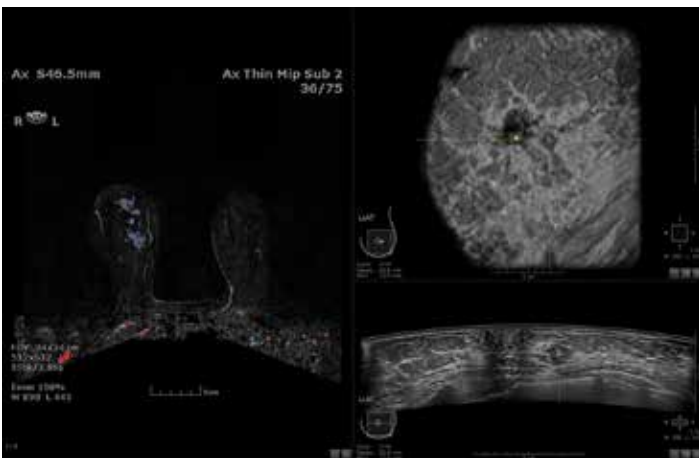
Normal Screening Mammogram (MLO View)



The coronal-transverse side-by-side hanging protocol provides multi-planar and multi-volume correlation between the left anterior-posterior and the left lateral views in this biopsy-proven invasive ductal carcinoma



The 3-on-1 hanging protocol allows for multi-planar correlation between the 3 orthogonal views of this biopsy-proven invasive ductal carcinoma



Comparison of MRI and Coronal-Transverse images

## Investigation and Diagnosis

Because the patient has extremely dense breasts, she was referred for an ABUS exam. Upon revealing an abnormality using ABUS, the patient was referred for a hand-held targeted ultrasound, followed by an ultrasound-guided core biopsy. A 9 mm invasive ductal carcinoma with no evidence of positive nodes was found in the left breast. Once the pathology was confirmed, the patient was referred for an MRI, for which no additional disease was found.

## Treatment

The patient and the surgeon together determined the appropriate treatment plan. As a result she underwent a lumpectomy and radiation. Due to the small size of the mass, mastectomy was not required. No enlarged lymph nodes were noted when scanning the axillary basin, therefore a SLN procedure was not performed. Based on the surgical pathology, she did not require chemotherapy.

## Discussion

“The cancerous mass was mammographically occult; however, ABUS was able to detect the cancer in this patient with extremely dense breast tissue. The cancer was invasive but small and node-negative. Early detection, while the mass was still small and before the cancer had metastasized, provided more options for the patient. In this case, the patient was able to choose breast-conserving surgery and she experienced a positive long-term outcome,” said Dr. Saini; “It is impressive to find cancers with ABUS that are node-negative. Even with invasive cancers, patients have more options and don’t necessarily have to undergo chemotherapy. A patient can have a lumpectomy, a shorter-course focal radiation and avoid more extensive surgery that has the chance of complications.” Dr. Saini concludes, “We wouldn’t have found the cancer without [ABUS]. We don’t know how long it would have taken for the cancer to have shown enough change on her mammogram for us to have detected it – it could have taken a year, maybe two.”



### Brief Statement

The Invenia ABUS is indicated as an adjunct to mammography or breast cancer screening in asymptomatic women for whom screening mammography findings are normal or benign (BI-RADS® Assessment Category 1 or 2), with dense breast parenchyma (BI-RADS Composition/Density C or D), and have not had previous clinical breast intervention. The device is intended to increase breast cancer detection in the described patient population. The Invenia ABUS may also be used for diagnostic ultrasound imaging of the breast in symptomatic women. See the device manual for detailed information, contraindications, warnings, precautions, potential adverse events.



## Dr. Monica Saini



Dr. Saini is a Radiologist specializing in breast imaging. Since 2008, she has practiced at Santa Fe Imaging in New Mexico, a facility performing diagnostic imaging studies for clients throughout the region. Dr. Saini earned her Bachelor of Science in Nursing at the University of Wisconsin in Madison, a Master of Science of Physiology at Rosalind Franklin

University and her medical degree from Rush Medical College in Chicago. Dr. Saini completed her Internship and Diagnostic Radiology Residency at the University of Wisconsin in Madison. Her Fellowship was in Women’s Imaging at the University of Washington in Seattle.

## Summary

ABUS has been shown to detect mammographically occult cancers in patients with dense breast tissue. Adding ultrasound to a screening program may increase cancer detection rates in women with dense breasts and help improve patient care.

For more information please contact your GE Healthcare sales representative, visit [www.gehealthcare.com/inveniaabus](http://www.gehealthcare.com/inveniaabus), or call (866) 281-7545.

1. Tabár L, et al. Swedish two-county trial: impact of mammographic. 2011;260:658-63.
2. Pisano et al. Diagnostic Performance of Digital versus Film Mammography for Breast-Cancer Screening. NEJM 2005;353:1773.
3. Mandelson et al. Breast density as a predictor of mammographic detection: comparison of interval- and screen-detected cancers. J Natl Cancer Inst 2000; 92:1081-1087.

## Imagination at work

[www.gehealthcare.com](http://www.gehealthcare.com). Product may not be available in all countries and regions. Contact a GE Healthcare Representative for more information.

Data subject to change.

© 2016 General Electric Company.

GE, the GE Monogram, imagination at work, and Invenia are trademarks of General Electric Company.

BI-RADS is a trademark of the American College of Radiology. Third party trademarks are the property of their respective owners.

Reproduction in any form is forbidden without prior written permission from GE. Nothing in this material should be used to diagnose or treat any disease or condition. Readers must consult a healthcare professional.